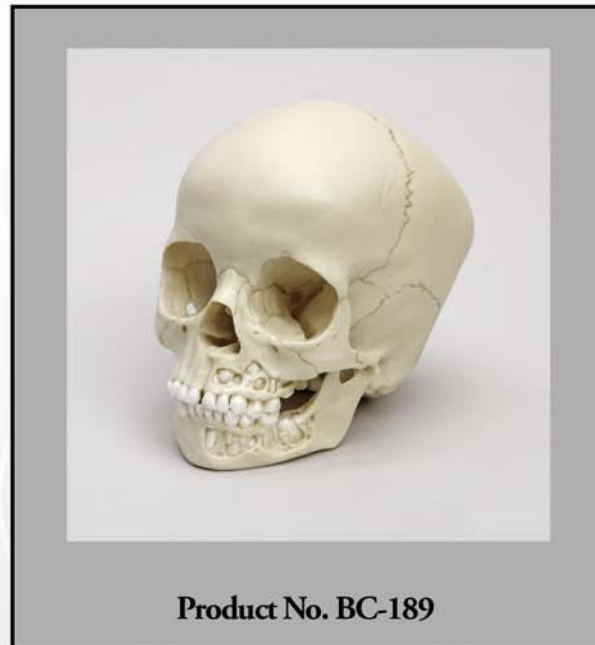


OSTEOLOGICAL EVALUATION

Prepared by
EVAN MATSHES BSc, MD
Consultant Osteologist



**Human 5-year-old Child Skull,
Dentition Exposed
(5-6 years)**



Bone Clones, Inc.

OSTEOLOGICAL REPRODUCTIONS

9200 Eton Ave. Chatsworth, CA 91311

Phone: (818) 709-7991 or (800) 914-0091 (USA only)

Email: info@boneclones.com Web: www.boneclones.com

© Bone Clones, Inc. 2015

Human, Child (5-6 years), teeth exposed

Product Number: BC-189

Specimen Evaluated: Bone Clones® replica

Skeletal Inventory:

- 1 intact cranium
 - cortical bone overlying buccal aspect of left maxilla has been dissected away
- 1 intact mandible
 - cortical bone overlying buccal aspect of left mandible has been dissected away

General observations:

**NOTE – The substance of this report is based on the evaluation of BC-188, the calvarium cut version of this skull; however, BC-189 features dissection of the cortical bone overlying the left maxillary and mandibular dental arcades.

In general, the molding process has preserved significant details necessary for evaluation. The general configuration of the skull is within normal limits. There is a slight asymmetry of the parietal eminence with the right projecting more posteriorly than the left. The general morphology of the individual visible cranial bones is within normal limits. Sutural patterns are of expected configuration. There is the (nasal) remnant of a partial metopic suture. The posterior intra-occipital sutures are fused. The anterior intra-occipital sutures are partially fused. There are bilateral epipteric bones. There are sutural bones (Wormian ossicles) along both right and left limbs of the lambdoid suture; there is a small sutural bone at the right asterion. The foramina are of expected configuration. The skull is atraumatic.

Dentition:

There are 12 teeth in the maxillary arcade and 13 teeth in the mandibular arcade.

The following teeth are present in the maxillae: 5.5 [A], 5.4 [B], 5.3 [C], 5.2 [D], 5.1 [E], 6.1 [F], 6.2 [G], 6.3 [H], 6.4 [I], and 6.5 [J].

The following teeth are present in the mandible: 7.5 [K], 7.4 [L], 7.3 [M], 7.2 [N], 7.1 [O], 8.1 [P], 8.2 [Q], 8.3 [R], 8.4 [S], and 8.5 [T].

The following teeth are beginning to erupt through the maxillary cortical bone: 1.6 [#3] and 2.6 [#14].

The following teeth are beginning to erupt through the mandibular cortical bone: 3.6 [#19], and 4.6 [#30].

The following unerupted (but exposed) tooth has evidence of calcification: 3.7 [#18].

The following empty gomphoses have features suggestive of early tooth calcification: 1.7 [2], 2.7 [#15], and 4.7 [#31].

There are no dental restorations or prostheses. There is no significant attrition.

Non-Dental Features of Age:

Fontanelles

The anterior fontanelle is closed. The posterior, sphenoidal (anterolateral) and mastoidal (posterolateral) fontanelles are closed. The speno-occipital synchondrosis is open. The calvarial sutures are all open (there is no evidence of ossification).

SUMMARY:

1. Age

Dental

~ 5 – 6 years.

Non-Dental

Likely greater than 1 year, less than 10.5 years.

Anterior fontanelle closed.

Median 13.8 months[1]

Range 4 – 26 months[2]

Posterior fontanelle closed.

2 – 3 months[3]

Sphenoidal (anterolateral) fontanelle closed.

2-3 months[3]

Mastoidal (posterolateral) fontanelle closed.

1 year[3]

Spheno-occipital synchondrosis open.

10.5 – 16 years[4, 5]

EDUCATIONAL RESOURCES:

1. This is an excellent example of a young child's skull.
2. It may be appropriate to discuss the differences between primary and secondary dentition, eruption patterns, and controversies surrounding the timelines that 'typify' those eruption patterns.
3. Age assessment of skeletal remains is best done in the context of the entire skeleton. It is important for educators to emphasize that when limited to the skull, age assessment of subadult remains is best done through a coordinated evaluation of such features as dentition and fontanelle closure, as well as radiographs and/or computed tomography (CT) scans. This is particularly key for studies of tooth development (calcification, eruption). It is important to emphasize that the evaluation of a skull without these methods is artificial and not reflective of actual practice. However, the ability to analyze such remains from the strict perspective of osteology is fundamental, and students must feel comfortable analyzing subadult skulls and skeletons.
4. It is not currently possible to reliably differentiate amongst the major racial groups within subadults nor is it possible to reliably differentiate male and female infant and young child skeletal remains.[6]
5. In the evaluation of subadult skulls, particularly when studying 'typical' eruption patterns, students must be cautioned that statistical data is based on **populations**, and may not necessarily be reflective of reality in an **individual**.
6. It may be appropriate to discuss the concept of sutural (Wormian) bones and what role they may play in the forensic evaluation of cranial remains. It is most important that students understand sutural bones are normal variants which may be present with somewhat increased frequency in some racial groups; they must not be misdiagnosed as fractures.
7. This specimen is excellent for all students learning about tooth development and eruption patterns.

Bone Clones® Osteological Evaluation Report

REFERENCES:

1. Kiesler, J. and Ricer, R. (2003). The abnormal fontanel. *American Family Physician*, 67(12): 2547-52.
2. Tunnessen, W.W., Jr. (1990). Persistent open anterior fontanelle. *JAMA*, 264(18): 2450.
3. Standring, S., Ed.(2005). *Gray's Anatomy: The Anatomical Basis of Clinical Practice*. 39 ed. London: Elsevier (Churchill Livingstone).
4. Konie, J. (1964). Comparative value of X-rays of the spheno-occipital synchondrosis and of the wrist for skeletal age assessment. *The Angle Orthodontist*, 34(4): 303-313.
5. Powell, T.V. and Brodie, A.G. (1963). Closure of the Spheno-Occipital Synchondrosis. *Anatomical Record*, 147: 15-23.
6. Matshes, E. and Lew, E. (2006). Forensic osteology. In *Forensic Pathology: Principles and Practice*, D. Dolinak, E. Matshes, and E. Lew, Editors. San Diego, CA: Elsevier (Academic Press).

DISCLAIMERS:

This report is meant only as a teaching tool for introductory level students of the anatomical, anthropology or forensic sciences who might be using this specimen to learn human and forensic osteology. Evaluation of osteologic material is best done with original specimens. My evaluation was based solely upon studies of a Bone Clones® replica. My opinions are based solely upon the material presented to me. This is somewhat artificial as in real forensic investigations additional studies would be undertaken prior to the formulation of diagnoses and the production of a report. These studies might include plain film radiography, computed tomography (CT) studies, histology, etc. Evaluation of a child skull for age always involves radiography. Osteologic/odontologic evaluation of age based purely on visible eruption patterns is a useful basic skill, but is artificial and not representative of actual practice. My opinions regarding this skull were made without access to the postcranial skeleton.

Evan Matshes BSc, MD
Consultant Osteologist