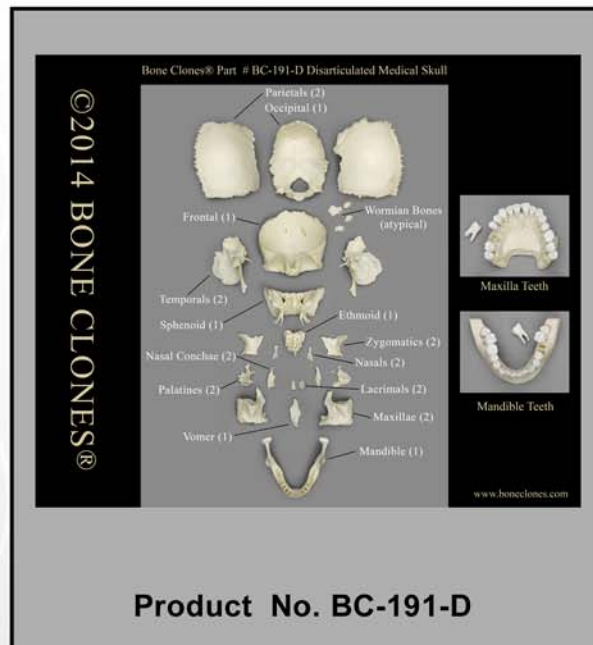


OSTEOLOGICAL TRACING OF CRANIAL NERVES

Prepared by
Noel T. Boaz, Ph.D., M.D.



Disarticulated Human Medical Study Skull



Bone Clones, Inc.

OSTEOLOGICAL REPRODUCTIONS

9200 Eton Ave. Chatsworth, CA 91311

Phone: (818) 709-7991 or (800) 914-0091 (USA only)

Email: info@boneclones.com Web: www.boneclones.com

© Bone Clones, Inc. 2015

Tracing the Cranial Nerves Osteologically

Noel T. Boaz, Ph.D., M.D.

Department of Anatomy
Ross University School of Medicine

<i>CN</i>	<i>Nucleus of Origin</i>	<i>Originating Space</i>	<i>Foramen – Enters bone</i>	<i>Foramen – Exits bone</i>	<i>Terminating Space</i>
I	Olfactory tracts of frontal lobe of cerebrum	Ant. cranial fossa	Cribriform plate of ethmoid	Cribriform plate of ethmoid	Sphenoethmoidal recess of nasal cavity (olfactory epithelium)
II	Optic tracts from optic chiasma and visual cortex of occipital lobe	Middle cranial fossa	Optic canal	Optic canal	Orbit (retina)
III	Motor nucleus of oculomotor in midbrain	Middle cranial fossa	Sup. orbital fissure	Sup. orbital fissure	Orbit (supplies levator palpebrae superioris, med. rectus, sup. rectus, inf. rectus, and inf. oblique muscles)
IV	Trochlear nucleus exiting dorsum of midbrain	Middle cranial fossa	“	“	Orbit (supplies sup. oblique m.)
V ₁ Supra-orbital nerve	Trigeminal ganglion (sensory)	Middle cranial fossa	“	Supraorbital notch	Forehead (sinciput)
Ant. & post. ethmoidal nn.	“ (through nasociliary nerve)	Orbit	Ant. & post. ethmoidal foramina	Ant. & post. ethmoidal foramina	Nasal cavity
Ext. nasal nerve	“ (through nasociliary nerve)	Orbit	Cribriform plate of the ethmoid	External nares (piriform aperture), emerging from groove on posterior of nasal bone	Dorsum and tip of nose
V ₂	Trigeminal ganglion (sensory)	Middle cranial fossa	Foramen rotundum	Foramen rotundum	Pterygopalatine fossa
Zygomatic nerve	“	Pterygopalatine fossa	Inferior orbital fissure	Zygomatofacial foramen	Orbit
Zygomatofacial nerve	“	Orbit	Zygomatocoorbital foramen	Zygomatofacial foramen	Face (malar region)
Zygomatotemporal nerve	“	Orbit	Zygomatocoorbital foramen	Zygomatotemporal foramen	Temporal fossa (supplies skin of the temple)
Sphenopalatine	“	Pterygopalatine	Sphenopalatine	Sphenopalatine	Nasal cavity

nerve		fossa	foramen	foramen	
Greater palatine nerve	“	“	Opening of pterygopalatine canal	Greater palatine foramen	Oral cavity
Infraorbital nerve	“	“	Inf. orbital fissure to infraorbital canal	Infraorbital foramen	Face
Pharyngeal nerve	“	“	Pharyngeal canal (palatovaginal+vomerovaginal canals)	Pharyngeal canal (palatovaginal+vomerovaginal canals)	Nasopharynx posterior to auditory tube
Ant. & middle superior alveolar nn.	“	Infraorbital canal	Sup. alveolar (ant.&middle) foramina	None - internal to maxilla	Interior of maxilla (to ant. & middle upper teeth)
Post. sup. alveolar n.	“	Infratemporal fossa	Post. sup. alveolar foramina	None – internal to maxilla	Interior to maxilla (post. upper teeth)
Nasopalatine nerve	“	Nasal cavity	Incisive foramen	Incisive foramen	Anterior hard palate
V ₃	Trigeminal nucleus (motor) and trigeminal ganglion (sensory)	Middle cranial fossa	Foramen ovale	Foramen ovale	Infratemporal fossa, ant. 2/3 of tongue (lingual n.), skin of cheek (buccal n.), mylohyoid & ant. belly digastric (n. to mylohyoid)
Recurrent meningeal nerve	“	Infratemporal fossa	Foramen spinosum	Foramen spinosum	Middle cranial fossa
Inferior alveolar nerve	“	Infratemporal fossa	Mandibular foramen		Interior of mandible (lower teeth)
Mental nerve	“	Interior of mandible	Mental foramen	Mental foramen	Chin
VI	Abducens nucleus	Middle cranial fossa	Sup. orbital fissure	Sup. orbital fissure	Orbit (supplies lat. rectus m.)
VII	Motor nucleus of VII	Posterior cranial fossa	Internal auditory meatus	Stylomastoid foramen	Infratemporal fossa
N. of pterygoid canal	“	Middle cranial fossa	Post. opening of pterygoid canal	Ant. opening of pterygoid canal	Pterygopalatine fossa
Gr. petrosal n.	Superior salivatory nucleus	Middle cranial fossa	Hiatus for greater petrosal nerve	Foramen lacerum/Hiatus of facial canal	Middle cranial fossa
Chorda tympani n.	Superior salivatory nucleus & nucleus solitarius	Posterior cranial fossa	Internal auditory meatus	Petrotympenic fissure	Condylar fossa
VIII	Vestibular and cochlear nuclei	Posterior cranial fossa	Internal auditory meatus	None – internal to inner ear	Cochlea and vestibule of inner ear
IX	Nucleus ambiguous, inferior salivatory	Posterior cranial fossa	Jugular foramen	Jugular foramen	Exterior of base of cranium

	nucleus, spinal nucleus of trigeminal, and nucleus solitarius				
Tympanic nerve	Inferior salivatory nucleus; inferior glossopharyngeal ganglion	Exterior of base of cranium (via middle ear)	Tympanic canaliculus	Hiatus for lesser petrosal nerve	Middle cranial fossa
Lesser petrosal n.	“	Middle cranial fossa	Hiatus for lesser petrosal nerve	Foramen ovale	Infratemporal fossa
X	Dorsal vagal nucleus, nucleus solitarius, nucleus ambiguus spinal nucleus of trigeminal	Posterior cranial fossa	Jugular foramen	Jugular foramen	Exterior of base of cranium
auricular n.	Dorsal vagal nucleus/Superior vagal ganglion	Exterior of base of cranium	Mastoid canaliculus	Tympano-mastoid fissure	Posterior of ear and inferior tympanic membrane
XI	Accessory nucleus in levels C1-5 of spinal cord	Exterior of base of cranium	Foramen magnum	Jugular foramen	Exterior of base of cranium
XII	Hypoglossal nucleus	Exterior of base of cranium	Hypoglossal canal	Hypoglossal canal	Exterior of base of cranium

Available also at:

<http://www.boneclones.com/pdf/BC-191-CranialNExercise-MotorSens.pdf>

Osteological Tracing of Cranial-Nerve Parasympathetics

CN	Nucleus of Origin	Originating Space	Foramen – Enters	Foramen – Exits	Site of Synapse	Delivering branch(es) of CNV	Terminating Space
III	Edinger-Westphal nucleus	Middle cranial fossa	Sup. orbital fissure	Sup. orbital fissure	Ciliary ganglion	Short ciliary nerves	Orbit
VII (Chorda tympani)	Superior salivatory nucleus	Middle cranial fossa	Internal auditory meatus (through posterior canaliculus into middle ear)	Petrotympenic fissure (out of middle ear to mandibular fossa)	Submandibular ganglion	Lingual nerve (V ₃)	Submandibular fossa (digastric triangle)
VII (Gr. petrosal n.)	Superior salivatory nucleus	Middle cranial fossa	Internal auditory meatus	Hiatus of facial canal	-	-	Middle cranial fossa
VII (N. of pterygoid canal ¹)	“ (fibers continue from greater petrosal nerve)	Middle cranial fossa	Post. opening of pterygoid canal	Ant. opening of pterygoid canal	Pterygopalatine ganglion	-	Pterygopalatine fossa
VII (secretomotor fibers)	“ (fibers continue from nerve of pterygoid canal)	Pterygopalatine fossa	Inferior orbital fissure	Inferior orbital fissure	-	Zygomatic nerve (V ₂) then lacrimal nerve (V ₁)	Orbit (lacrimal fossa)
IX (secretomotor fibers)	Inferior salivatory nucleus	Posterior cranial fossa	Jugular foramen	Jugular foramen	-	-	Exterior of base of cranium
IX (tympanic nerve)	“ (fibers continue from main branch CN IX)	Exterior of base of cranium	Tympanic canaliculus (to tympanic plexus in middle ear)	Hiatus for lesser petrosal nerve	-	-	Middle cranial fossa
IX (lesser petrosal nerve)	“ (fibers continue from tympanic nerve via tympanic plexus)	Middle cranial fossa	Hiatus for lesser petrosal nerve	Foramen ovale	Otic ganglion	Auriculotemporal nerve (V ₃) (p-s root flows around middle meningeal artery)	Infratemporal fossa
X (secretomotor fibers)	Dorsal motor nucleus of vagus	Posterior cranial fossa	Jugular foramen	Jugular foramen	Walls of abdominopelvic viscera	-	Exterior of base of cranium

¹ The nerve of the pterygoid canal, also known as “Vidian nerve,” is formed when the greater petrosal nerve merges with the deep petrosal nerve, composed of sympathetic fibers following the internal carotid artery and entering the skull through the carotid canal.