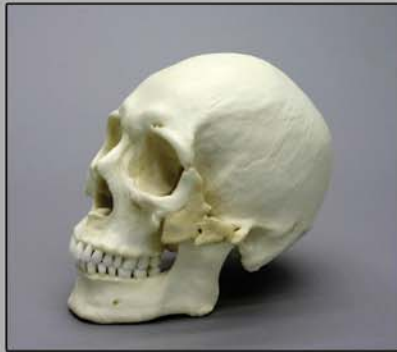

OSTEOLOGICAL EVALUATION

Prepared by
Karen Ramey Burns, Ph.D.
Forensic Anthropologist



Product No. BC-303

Human Healed Trauma Skull



Bone Clones, Inc.

OSTEOLOGICAL REPRODUCTIONS

9200 Eton Ave. Chatsworth, CA 91311

Phone: (818) 709-7991 or (800) 914-0091 (USA only)

Email: info@boneclones.com Web: www.boneclones.com

© Bone Clones, Inc. 2015

Human Healed Trauma Skull

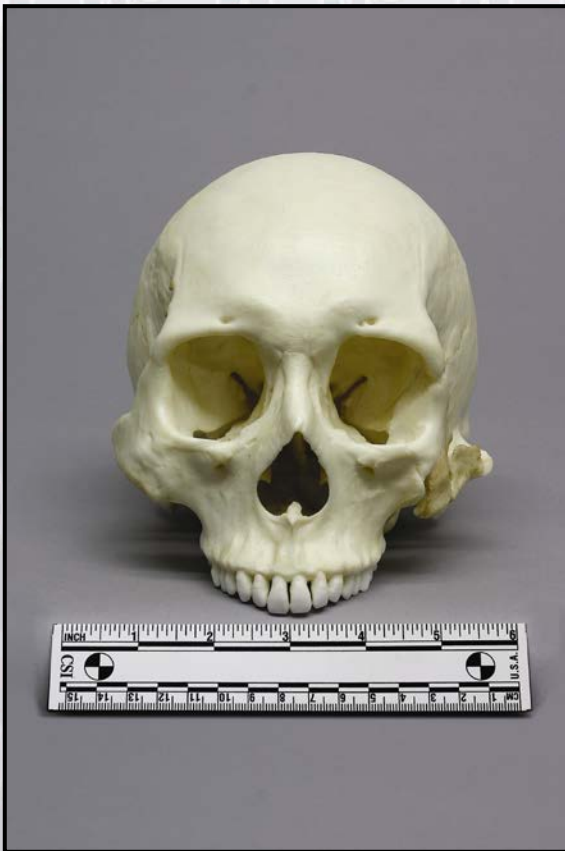Product Number: BC-303

Specimen Evaluated: Original Specimen

Skeletal Inventory: 1 Cranium with full dentition (teeth ##1-16)
1 Mandible with full dentition (teeth ##17-32)

Osteological Observations:

The examined specimen includes a complete cranium and mandible. The skull is in very good condition. The sutures are fused throughout the neurocranium and the teeth are near-perfect. (See Figure 1.)



The temporomandibular joint articulates well and the maxillary and mandibular dentition occlude accurately. There is no evidence to suggest more than one individual.

The most impressive feature of the skull is a shattered and healed left zygoma. The surrounding bone is also affected. The trauma section provides a detailed description.

Postmortem damage to the skull is minimal and consists of a broken right styloid process and a perforated left palatal process of the palatine bone. There is also some slight postmortem chipping of the tooth enamel.

Figure 1: Frontal View of Cranium

Dentition:

The skull contains a full set of 32 permanent teeth. They appear to have been glued in place after the skull was cleaned. Overall, the teeth were in good condition at the time of death. Some calculus encrusts the maxillary molar teeth, and some reactive bone is present in the maxillary alveolar ridge (evidence of periodontal disease), but there are no obvious carious lesions. (See Figure 2.) No antemortem breaks are apparent, but several postmortem enamel chips are present (##15, 17, 30, 32). This is a common occurrence in dry specimens.

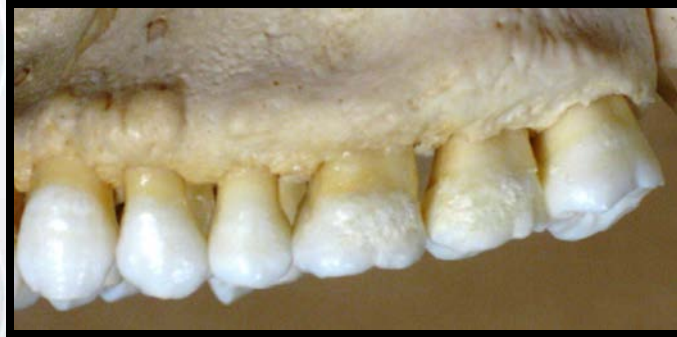
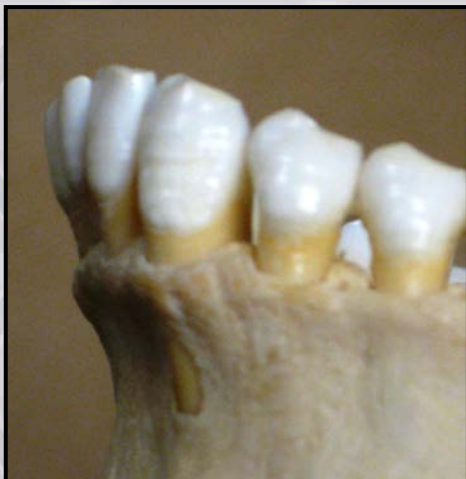
Figure 2: Periodontal disease and mild calculus deposition

Mild abrasion has exposed the dentin on the incisal edges of the anterior teeth as well as the cusp apices of the canines and lower premolars. The enamel of the molar cusps is slightly abraded, but dentin is exposed only slightly on the first molars. The abrasion is more pronounced on the right side, possibly related to the antemortem trauma of the left zygoma and temporomandibular joint.

The teeth are in good alignment with the exception of moderate rotation of the lower right lateral incisor (#26). The lingual surface of #26 overlaps #27 on the mesiolabial edge.

All of the anterior teeth display horizontal lines in the enamel. This condition is known as enamel hypoplasia. This suggests that the individual sustained bouts of poor nutrition as a child, during the formation of the permanent teeth within the alveolar bone. (See Figure 3.)



The second and third molars lack enamel hypoplasia. It is possible that the diet of the individual improved in later childhood during the time when the last of the adult molars were forming enamel.

Figure 3: Enamel hypoplasia

Features of Race:

Insufficient information is present for a clear determination of genetic origin. The skull is more consistent with European origin than North American Indian or African, but it is not a typical European-derived North American white.

The maxillary incisors demonstrate slight “shoveling,” a trait consistent with Native American or Asian origin. The degree of shoveling, however, is not sufficiently developed to be convincing as a racial trait. (See Figure 4.)

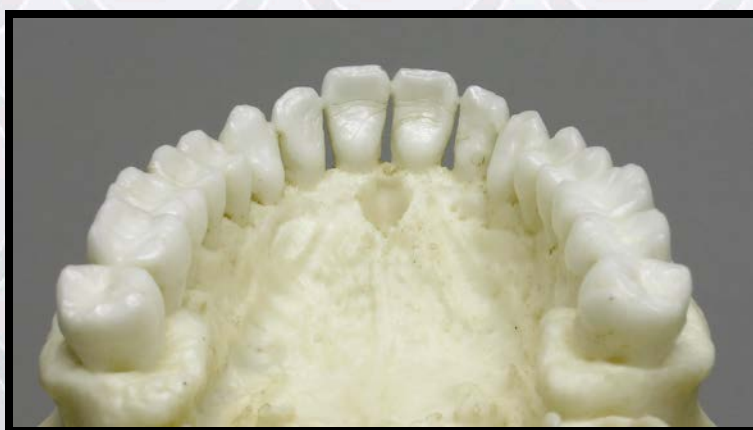

Figure 4: Maxillary dentition with good alignment, no restorations, and slightly shovel-shaped incisors

Cranial measurements processed by multiple discriminate function analysis demonstrate a consistency with the group called “Hispanic Male.” This suggests a genetic admixture that includes both European and Native American or Asian (Ousley and Jantz, 2005).

Features of Sex:

The cranium is most probably from a male individual, determined by the frontal bone configuration which displays a prominent frontal sinus area. The mastoid processes are not large, but the zygomatic extension is impressive and the nuchal ridge is significant, both suggesting male. The mandible is also masculine-looking. The chin is prominent, and the gonial angle is close to 90% and flared.

Features of Age:

The cranial sutures are remarkably well-fused, giving an appearance of advanced age, but sutures are a very poor trait for age estimation (Galera, Ubelaker et al., 1998). The teeth, on the other hand, give the appearance of a young adult.

Trauma:

There is a healed comminuted fracture of the left cheek bones, with associated injuries to the jaw, throat, and eye orbit. It involves damage to the zygoma, zygomatic arch, temporomandibular joint, and styloid process of the temporal bone. The zygoma was broken in at least three places. The fragments were displaced medially, and healed without proper alignment. Both the zygo-frontal suture and the zygo-maxillary suture are levered open and the zygomatic arch is broken in two places and healed tenuously.

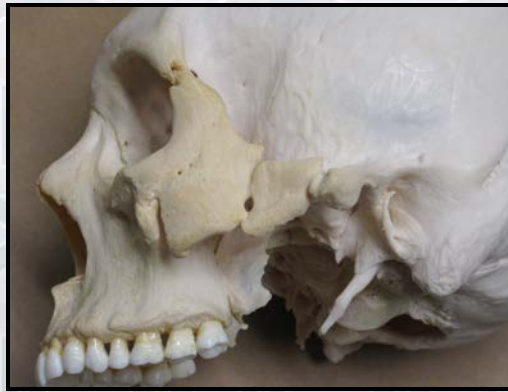
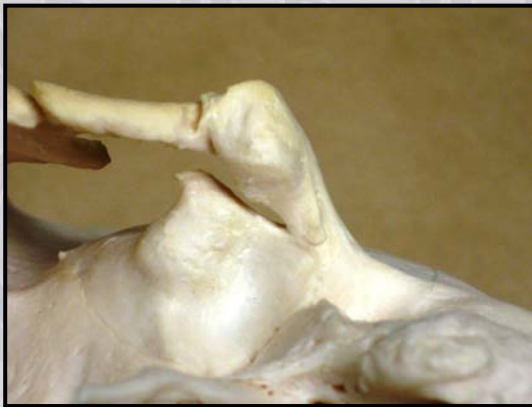
Figure 5: Fractured and healed cheek bones and styloid process

The lateral wall of the left orbit bulges into the eye socket, and the left temporomandibular joint (TMJ) is fractured and healed without complete union.



In correlation with the temporomandibular joint fracture, both mandibular condyles are remodeled to the extent that they are flattened on the posterior surfaces. The right TMJ has undergone more remodeling than the left, possibly because tension was avoided in the fractured left joint and masticatory stress was transferred to the bones of the right joint.

Figure 6: Left TMJ with persisting fracture

The styloid process of the left temporal bone is also broken and healed. (See Figure 7.) (The right is absent.) The styloid process is important to the function of the tongue and neck. It provides attachment for the styloglossus, stylohyoid, and stylopharyngeus muscles as well as the stylohyoid and stylomandibular ligaments. Trauma to the styloid process can cause an array of physical symptoms including neck pain, and difficulty in swallowing or turning the head.

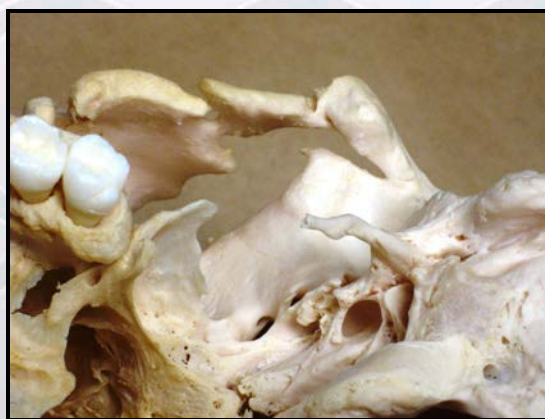


Figure 7 Left styloid process fracture

There is no evidence of medical treatment of this massive facial wound. As a result, the individual suffered loss of normal jaw and neck function as well as facial distortion. He probably also experienced chronic pain from his injuries.

SUMMARY:

1. Race: Not possible to make clear determination but consistent with group called "Hispanic."
2. Sex: Male.
3. Age: Although cranial sutures are remarkably well-fused, dentition suggests young adult.

4. Trauma: The zygoma was broken in at least three places. The fragments were displaced medially, and healed without proper alignment.

Educational Resources:

1. This is an excellent skull displaying not only major facial trauma (healed without effective medical treatment), but also subsequent modification of the eye orbit, temporomandibular joints and styloid process. The educator may wish to use the styloid process damage to discuss Eagle's syndrome in which a broken or elongated styloid process adversely affects surrounding tissues. (See Olusesi, 2006; Rechtweg & Wax, 1998.)
2. Educators may want to use this skull as a launching point for the discussion of racial admixture and the risks of jumping to conclusions in racial designation.
3. The dentition of this skull provides the opportunity to discuss the signs of nutritional stress. Enamel hypoplasia appears on the anterior teeth but not on second and third molars, suggesting that the individual sustained bouts of poor nutrition as a child. It is quite possible that this person's living conditions changed during development of the final molar teeth. Immigrant status is suggested.
4. The complexity of determining age without the entire skeleton should be explained. In this skull, the fusion of the cranial sutures would suggest an age much older than would the dentition.

References:

Galera, V., D. Ubelaker et al. (1998). Comparison of macroscopic cranial methods of age estimation applied to skeletons from the Terry Collection. *Journal of Forensic Sciences*, **43**(5):933-9.

Olusesi, A.D. (2006). Traumatic Eagle Syndrome: Does Neck Trauma Result in Complete Ossification in Partially Ossified Stylohyoid Ligament? *The Internet Journal of Otorhinolaryngology*, **4**(2).

Ousley S.D., & Jantz, R.L. (2005). FORDISC 3.0: Personal Computer Forensic Discriminant Functions. Knoxville, TN: University of Tennessee, Department of Anthropology, Forensic Anthropology Center.

Rechtweg, J.S., & Wax, M.K. (1998). Eagle's syndrome: A review. *American Journal of Otolaryngology*, **19**(5): 316-321.

Disclaimers:

This report is meant only as a teaching tool for introductory level students of the anatomical, anthropology or forensic sciences who might be using this specimen to learn human and forensic osteology. My opinions are based solely upon the material presented to me. This is somewhat artificial as in real forensic investigations additional studies would be undertaken prior to the formulation of diagnoses and the production of a report. These studies might include plain film radiography, computed tomography (CT) studies, histology, etc. My opinions regarding race and sex are based only upon non-metric analyses. Evaluation of cranial suture closure is most accurately assessed endocranially as the sutures

Bone Clones ® Osteological Evaluation Report

are known to close from the endocranial table towards the ectocranium. My opinions regarding this skull were made without access to the postcranial skeleton.

Karen Ramey Burns, Ph.D.
Forensic Anthropologist