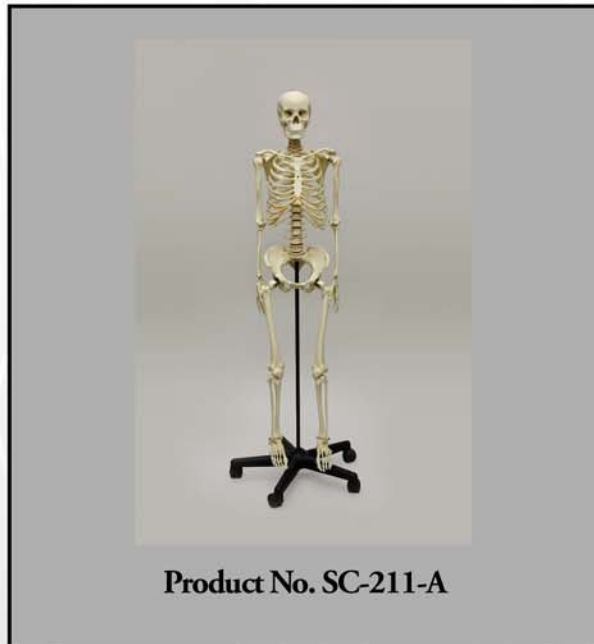

OSTEOLOGICAL EVALUATION

Skull evaluated by
Tori Randall, Ph. D.
Biological Anthropologist

Post-cranial skeleton evaluated by
Evan Matshes BSc, MD
Consultant Osteologist



Human Female Asian Articulated Skeleton



Bone Clones, Inc.

OSTEOLOGICAL REPRODUCTIONS

9200 Eton Ave. Chatsworth, CA 91311

Phone: (818) 709-7991 or (800) 914-0091 (USA only)

Email: info@boneclones.com Web: www.boneclones.com

© Bone Clones, Inc. 2016

Human, Asian Female

PRODUCT NUMBER: SC-211
SEE ACCOMPANYING SKULL EVALUATION

SPECIMEN EVALUATED: Bone Clones® replica

SKELETAL INVENTORY: 1 intact cranium (see accompanying skull evaluation)
1 intact mandible (see accompanying skull evaluation)
1 complete postcranial skeleton

GENERAL OBSERVATIONS:

In general, the molding process has preserved significant details necessary for evaluation. The remains are totally skeletonized.

OSTEOLOGIC OBSERVATIONS:

General shape and configuration of the individual bones is within normal limits.

There is prominent osteophytic lipping giving some bones a mild to moderately robust appearance; this is most prominent along the anterior margins of the vertebral centra, the innominates (especially at the sacro-iliac joints), and at the xiphisternum. There is no acute/recent trauma.

SEX DETERMINATION:

Pelvic morphology:

The pelvic inlet is somewhat rounded. The innominate bones are somewhat robust, and sites for musculofascial attachment are slightly to moderately prominent. The ilium is not prominent in the superoinferior plane (i.e., does not extend vertically). There are subtle preauricular sulci. The greater sciatic notch is broad. The subpubic angle is obtuse. The pubis is prominently widened. There is no ventral arc. There are deep, smooth pits (“pits of parturition”) on the posterior surface of pubic portions of the left innominate. There is a slight subpubic concavity. The ischiopubic ramus is slightly thickened, and its medial aspect is somewhat rounded. The obturator foramen is somewhat small and triangular.

The sacrum is short, broad, and prominently curved (in the anteroposterior plane).

The totality of pelvic features is most in keeping with female sex.[1-4]

Femoral head diameter:

The diameter of the femoral head is 39 mm. This is suggestive of female sex.[5, 6]

Radial head diameter:

The maximum diameter of the radial head is 19 mm. This is suggestive of female sex.[7]

The totality of features is most in keeping with female sex.

AGE DETERMINATION:

Epiphyseal Union:

All of the epiphyseal growth plates are fused. This suggests that the individual was older than 20 years at the time of death.[8]

Albert Method for Evaluation of Vertebral Centra Epiphyseal Union:

The pattern and stage of vertebral centra epiphyseal union are in keeping with an Albert score of 3. This suggests that the individual was in their middle 20's or older.[9]

Todd Pubic Symphysis Scoring System:

Degenerative features on the pubic symphyseal surface are in keeping with Todd phase 9. This suggests that the individual was 45 to 49 years old at the time of their death.[10, 11]

Suchey-Brooks Pubic Symphyseal Phase:

Degenerative features on the pubic symphyseal surface are in keeping with a Suchey-Brooks phase V. This suggests that the individual was 48.1 years +/- 14.6 years (95% confidence interval 25-83 years) at the time of death.[12]

iScan-Loth Rib Phase Analysis*:

Degenerative features at the sternal end of the right fourth rib are in keeping with iScan-Loth phase 5.** This suggests that the individual was 33-46 years old at the time of death.[13-16]

The preponderance of evidence suggests that this was an adult between 30 and 50 years of age.

* Note: Assessment of iScan-Loth rib phase is very difficult if not impossible on cast specimens. Not only is an evaluation of very fine detail necessary (which may not be possible with some casts), but an estimation of bone weight, porosity, friability, etc., is required, and not possible without access to the original specimen.

** Note: Descriptive statistics for "white female" were applied as data for "Asian female" was not available.

DETERMINATION OF STATURE:

Measurements were taken from RIGHT-sided elements.

Humerus 27.2 cm
Estimated height = 143.6 cm +/- 4.25 cm

Radius 20.3 cm
Estimated height = 141.6 cm +/- 4.60

Ulna 22.0 cm
Estimated height = 141.7 cm +/-4.66 cm

Femur 39.0 cm
Estimated height = 143.9 cm +/-3.80 cm

Tibia 31.0 cm
Estimated height = 143.1 cm +/- 3.27 cm

Fibula 30.5 cm
Estimated height = 141.5 cm +/- 3.24 cm

*The totality of data produced by regression equation calculations suggests that the individual stood between 137 cm and 148 cm tall.[10]***

*** Note: Height is estimated for an Asian female through utilization of regression equations for Asian males, and multiplying the resultant score by 0.92.

SUMMARY:

1. Sex: Female.
2. Age: Most likely 30 to 50 years.
3. 137 cm. to 148 cm.
4. No evidence of trauma.
5. Unique identifying features.

Mild to moderate degree of osteoarthritic changes:

- Anterior vertebral centra
- Sacroiliac joints
- Innominate bones

EDUCATIONAL RESOURCES:

1. This is an excellent example of an adult skeleton.
2. Age assessment of skeletal remains is best done in the context of the entire skeleton. Integration of data from a broad set of studies is optimal. Investigators should offer the age range most safely suggested by the totality of studies. Students must be cautioned that statistical data is based on **populations**, and may not necessarily be reflective of reality in an **individual**.
3. Assessment of sex is best done through an evaluation of all available skeletal elements. That said, the pelvis is the most reliably sexually dimorphic element. Many other bones (including, especially, some of the long bones) can be used with some degree of reliability to determine sex. Many resources exist to assist students with such endeavors.[6]

REFERENCES:

1. Phenice, T.W. (1969). A newly developed visual method of sexing the os pubis. *Am J Phys Anthropol*, 30(2): pp. 297-301.
2. Matshes, E. and Lew, E. (2006). Forensic osteology. In *Forensic Pathology: Principles and Practice*, D. Dolinak, E. Matshes, and E. Lew, Editors. San Diego, CA: Elsevier (Academic Press).
3. Bennett, K. (1993). *A Field Guide for Human Skeletal Identification*. 2 ed. Springfield, IL: Charles C. Thomas.
4. Krogman, W. and Iscan, M. (1986). *The Human Skeleton in Forensic Medicine*. 2 ed. Springfield, IL: Charles C. Thomas.
5. Mall, G., et al. (2000). Determination of sex from femora. *Forensic Sci Int*, 113(1-3): pp. 315-21.

Bone Clones® Osteological Evaluation Report

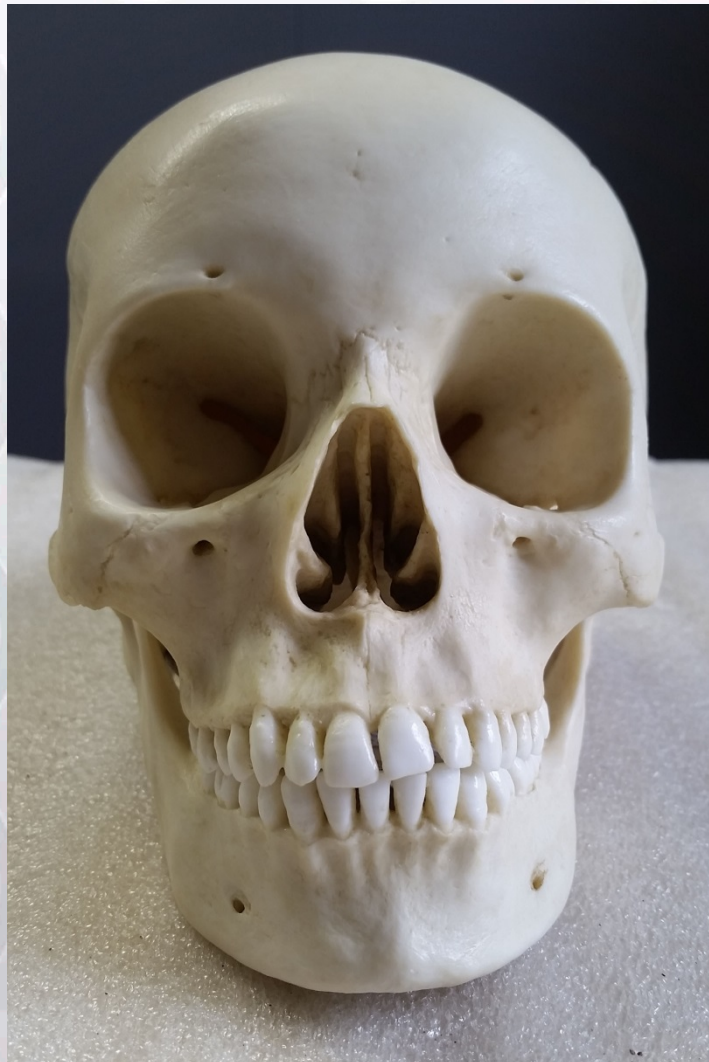6. Bass, W. (1995). *Human Osteology: A Laboratory and Field Manual*. Columbia, MO: Missouri Archeological Society.
7. Berrizbeitia, E.L. (1989). Sex determination with the head of the radius. *J Forensic Sci*, 34(5): pp. 1206-13.
8. Stewart, T. (1970). *Personal Identification in Mass Disasters*. Washington, DC: National Museum of Natural History.
9. Albert, A.M. and Maples, W.R. (1995). Stages of epiphyseal union for thoracic and lumbar vertebral centra as a method of age determination for teenage and young adult skeletons. *J Forensic Sci*, 40(4): pp. 623-33.
10. Ubelaker, D. (1999). *Human Skeletal Remains: Excavation, Analysis, Interpretation*. 3 ed. Washington, DC: Taxacum Press.
11. Buikstra, J. and Ubelaker, D. eds. (1994). *Standards for Data Collection from Human Skeletal Remains: Proceedings of a Seminar at the Field Museum of Natural History Organized by Jonathan Haas*. Arkansas Archeological Survey Research Series No. 44. Fayetteville, AR: Arkansas Archeological Survey.
12. Brooks, S. and Suchey, J. (1990). Skeletal age determination based on the os pubis: a comparison of the Acsadi-Nemeskeri and Suchey-Brooks methods. *Human Evolution*, 5(3): pp. 227-238.
13. Iscan, M.Y., Loth, S.R. and Wright, R.K. (1984). Age estimation from the rib by phase analysis: white males. *J Forensic Sci*, 29(4): pp. 1094-104.
14. Iscan, M.Y., Loth, S.R. and Wright, R.K. (1985). Age estimation from the rib by phase analysis: white females. *J Forensic Sci*, 30(3): pp. 853-63.
15. Iscan, M.Y. and Loth, S.R. (1986). Determination of age from the sternal rib in white males: a test of the phase method. *J Forensic Sci*, 31(1): pp. 122-32.
16. Iscan, M.Y., Loth, S.R. and Wright, R.K. (1987). Racial variation in the sternal extremity of the rib and its effect on age determination. *J Forensic Sci*, 32(2): pp. 452-66.

DISCLAIMERS:

This report is meant only as a teaching tool for introductory level students of the anatomical, anthropology or forensic sciences who might be using this specimen to learn human and forensic osteology. Evaluation of osteologic material is best done with original specimens. My evaluation was based solely upon studies of a Bone Clones® replica. My opinions are based solely upon the material presented to me. This is somewhat artificial as in real forensic investigations additional studies would be undertaken prior to the formulation of diagnoses and the production of a report. These studies might include plain film radiography, computed tomography (CT) studies, histology, etc.

Osteological Evaluation

*Prepared by
Tori D. Randall, Ph.D.
Biological Anthropologist*



Adult Female Asian Skull

Product Number: BC-299

Specimen Evaluated: Bone Clones® replica

Skeletal Inventory: Cranium and mandible

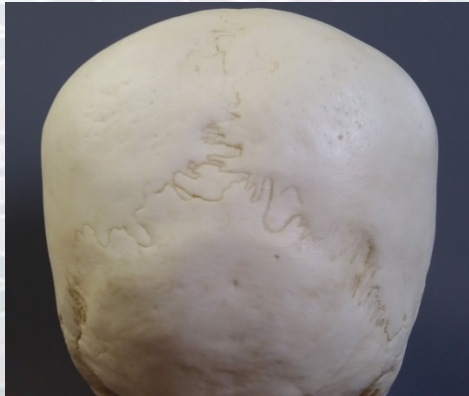
Bone Clones® Osteological Evaluation Report

Osteological Observations:

In general, the casting process has preserved sufficient details necessary for evaluation.

Features of Age:

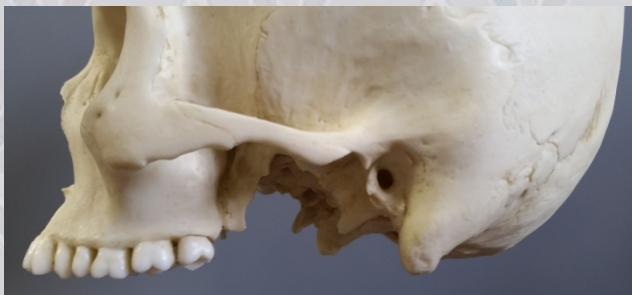This skull has been classified as an adult based on the presence of permanent dentition. Furthermore, the skull has been classified as a younger adult. This is based on the incomplete eruption of the lower left third molar and upper right third molar. This is also based on the degree of cranial suture closure, even though there is considerable variability in closure rates (Meindl and Lovejoy, 1985). In addition, miscellaneous traits were evaluated for general indications of whether the skull is from a younger or older adult. Age-related changes such as dental wear and osteoarthritis distinguish older adults from younger adults (Buikstra and Ubelaker, 1994). This skull does not exhibit any evidence of osteoarthritis or dental wear.



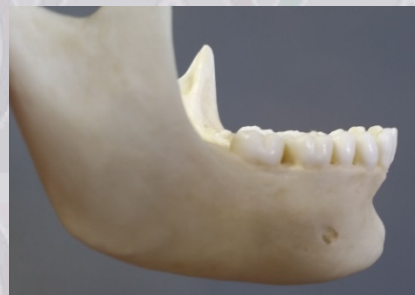Posterior view of skull showing open cranial sutures.

Features of Sex:

Sex is determined most accurately by looking at traits on the pelvis and skull (Mays, 1998); the pelvis being the most reliable indicator (Buikstra and Ubelaker, 1994; Bass, 1995; Schwartz, 1995; White and Folkens, 2000). The absence of the pelvis in this case meant that determination of sex had to be made by visually scoring a variety of sexually dimorphic skeletal criteria evident in the skull. Morphological features such as the lack of robusticity of the nuchal crest, the small size of the mastoid process, the sharpness of the supraorbital margin, the lack of prominent muscle markings, and the projection of the mental eminence on the mandible suggest that this is a female (Buikstra and Ubelaker, 1994; Bass, 1995; White and Folkens, 2000).



Small mastoid process.



Mental eminence.

Bone Clones® Osteological Evaluation Report

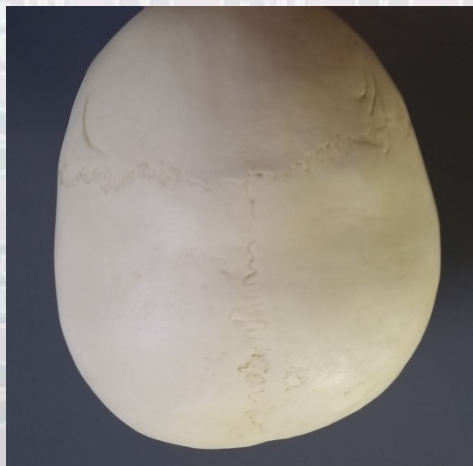
Features of Ancestry:

Several morphological traits of the skull were used to determine the Asian ancestry of this individual. For example, the nasal root is long and narrow, the lower nasal border is flat and sharp with a small anterior nasal spine, and there is mild prognathism. All of these features are morphological traits indicative of Asians.

Trauma and Pathology:

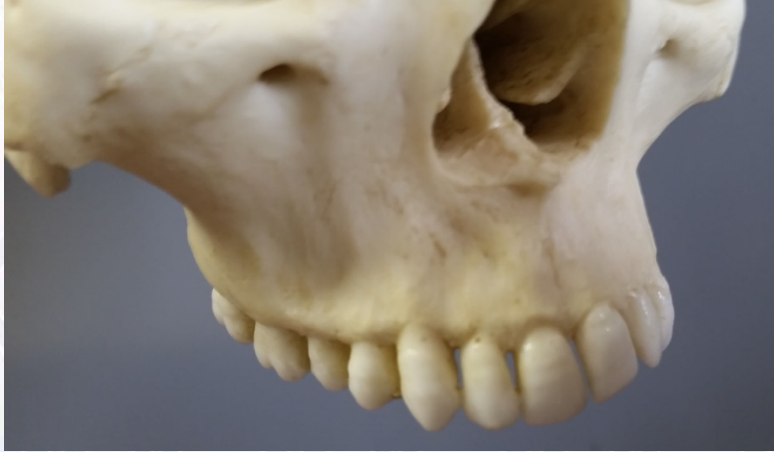There is evidence of healed blunt force trauma along the right lambdoid suture. The lesion has a well-defined circular shape, and the absence of reactive bone rules out an infectious etiology.

There is evidence of artificial cranial modification (oftentimes referred to as cradleboard deformation) on the skull. Artificial cranial modification is deformation of the cranium as a result of an infant's head resting against a board for long periods of time during its development (Brothwell, 1981; White and Folkens, 2000). In some cultures, people strap their infants onto a board called a cradleboard, and then carry it and the baby on their back. During this cranial development stage, the cranial vault flattens where it has been pressed against the cradleboard.



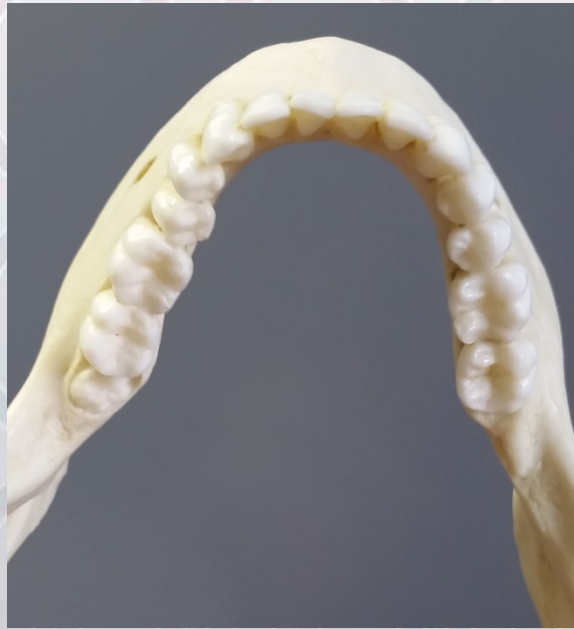Artificial cranial modification.

There are linear enamel hypoplasias on the dentition. Growth arrest (when the cells responsible for tissue development are disrupted) is indicative of physiological stress during skeletal and dental development, and can lead to linear enamel hypoplasias. Canine teeth may be exclusively observed for evidence of linear enamel hypoplastic defects as indicators of overall metabolic stress. Canines are often used because the development of the crown takes slightly longer than other teeth (Berbesque and Doran, 2008). There are linear enamel hypoplasias on all of the canine teeth (as well as others) in this skull.



Linear enamel hypoplasias.

There is an impacted lower left third molar, and agenesis of the lower right third molar.



Impaction and agenesis of third molars.

SUMMARY:

1. Adult female Asian skull.

Educational Resources:

1. This is an excellent example of an adult female Asian skull.
2. All of the developmental skeletal changes are complete, which makes this a good candidate for discussing morphological traits in adults.

Bone Clones® Osteological Evaluation Report

References:

Bass WM. 1995. Human osteology: A laboratory and field manual of the human skeleton. Columbia: Missouri Archaeological Society.

Berbesque JC, Doran GH. 2008. Physiological stress in the Florida Archaic – Enamel hypoplasia and patterns of developmental insult in early North American hunter-gatherers. *American Journal of Physical Anthropology* 136: 351-356.

Brothwell DR. 1981. Digging up bones. New York: Cornell University Press.

Buikstra JE, Ubelaker DH. 1994. Standards for data collection from human skeletal remains: Proceedings of a seminar at the Field Museum of Natural History. Fayetteville: Arkansas Archeological Survey Press.

Mays SA. 1998. The archaeology of human bones. London: Routledge.

Meindl RS, Lovejoy CO, et al. 1985. Accuracy and direction of error in the sexing of the skeleton: Implications for paleodemography. *American Journal of Physical Anthropology* 68: 79-85.

Schwartz JH. 1995. Skeleton keys: An introduction to human skeletal morphology, development, and analysis. New York: Oxford University Press.

White TD, Folkens PA. 2000. Human osteology. San Diego: Academic Press, Inc.

Disclaimers:

This report is meant only as a teaching tool for introductory level students of the anatomical, anthropology, or forensic sciences who may be using this specimen to learn about human osteology. Evaluation of skeletal material is best done with original specimens. My evaluation was based solely upon studies of a Bone Clones® replica. My opinions are based solely upon the material presented to me, and are based only upon non-metric analyses.