

OSTEOLOGICAL EVALUATION

Prepared by
Tori D. Randall, Ph.D.
Biological Anthropologist



Human Male European Articulated Skeleton



Bone Clones, Inc.

OSTEOLOGICAL REPRODUCTIONS

9200 Eton Ave. Chatsworth, CA 91311

Phone: (818) 709-7991 or (800) 914-0091 (USA only)

Email: info@boneclones.com Web: www.boneclones.com

© Bone Clones, Inc. 2015

Human Male European Articulated Skeleton

Product Number: SCM-192-A

Known Information:

All bones are associated in this skeleton of a 34-year-old European male, who stood 5' 8" and weighed 185 pounds at time of death. Cause of death was a gunshot wound to the right arm and chest. Information about this individual was documented at the time of his death.

Maxwell Museum of Anthropology:

The Maxwell Museum of Anthropology's Laboratory of Human Osteology, at the University of New Mexico, specializes in numerous facets of physical anthropology. The laboratory serves as a repository of human remains and includes prehistoric, historic, documented, and forensic remains.

Established in 1984 by Dr. J. Stanley Rhine, the Maxwell Museum's Documented Skeletal Collection has grown to include 237 individuals (as of July 2005) encompassing both sexes, all ages, and many population groups. The skeletal remains are obtained by donation, either by the individual before death, or by the family of a deceased loved one. Information on the sex, age, population affinity, and cause of death is available for the majority of these individuals, allowing students and visiting researchers to develop and test new techniques and theories.

Since 1995, prospective donors or their families have been asked to provide health and occupational data as well. With this information, researchers are able to examine the skeletal manifestations of particular diseases including degenerative joint and disc diseases, lymphoma, and osteoporosis, as well as the reaction of bone to repetitive motions and trauma. Recent research has included efforts towards the identification of handedness in individuals, determination of body mass from the skeleton, and variation in cranial damage from various projectiles. The importance of the Documented Collection cannot be overstated. No other institution in the American West has as large a collection of human skeletal remains with such extensive demographic data.

Bone Clones is grateful to the Maxwell Museum for allowing us to select specimens for reproduction from their valuable collection and granting us exclusive casting rights to these pieces.

Human Male European Articulated Skeleton

Product Number: SCM-192-A
Specimen Evaluated: Bone Clones® replica
Skeletal Inventory: Complete skeleton

Osteological Observations:

This is a complete adult human skeleton with 32 teeth. Since there are no duplicate skeletal elements, and the bones from the right and left side of the body are consistent in size and shape, it is possible to conclude that there is only one individual represented.

Dentition:

The skull exhibits full adult dentition. There is no evidence of carious lesions or dental abscessing. The right mandibular premolars and first molar show signs of wear, as does the left mandibular M1, but there is not excessive dental attrition. There is slight root exposure, which is evidence of periodontal disease.

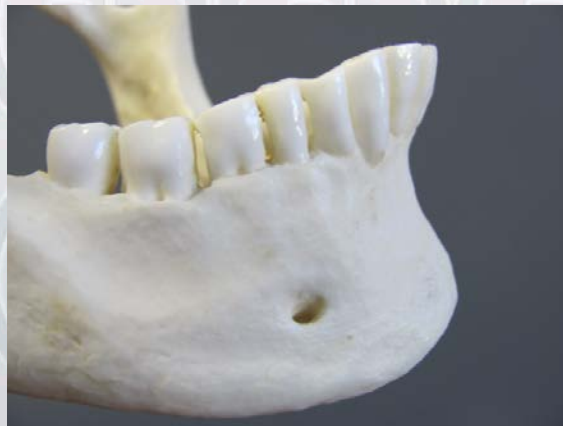

Figure 1: Right mandibular dentition with evidence of attrition and periodontal disease.

Features of Sex:

The features of the pelvis are typical of a male. Determination of sex was made by visually scoring a variety of sexually dimorphic skeletal criteria. Sex is determined most accurately by looking at traits on the pelvis and skull (Mays, 1998), the pelvis being the most reliable indicator (Buikstra and Ubelaker, 1994; Bass, 1995; Schwartz, 1995; White and Folkens, 2000). Morphological features of the pelvis such as a ventral arc, subpubic concavity, and ischiopubic ramus ridge were all absent. The absence of these features, typically expressed in females (Phenice, 1969), suggests that this is a male. Additional attributes including the overall size of the pelvic outlet (White and Folkens, 2000) and breadth of the greater sciatic notch (Buikstra and Ubelaker, 1994) were also used in sex determination. The pelvic outlet is small, and the greater sciatic notch, as well as the subpubic angle, is narrow. The total pelvis shape is also high and narrow, which is consistent with male morphology.

Males tend to have larger, more robust skulls than females. In this case, the morphology of the skull was consistent with that of the male sex. Various cranial characteristics were evaluated: the presence of a robust nuchal crest, large mastoid processes, a blunt supraorbital margin, and the square mental eminence on the mandible (Buikstra and Ubelaker, 1994; Bass, 1995; White and Folkens, 2000).

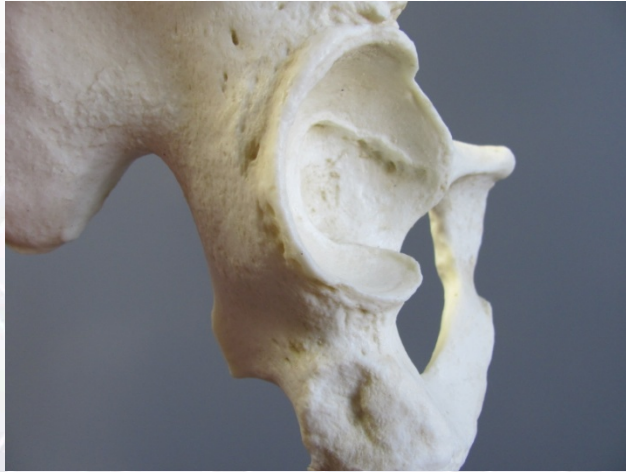

Figure 2: The greater sciatic notch is narrow, which is indicative of males.

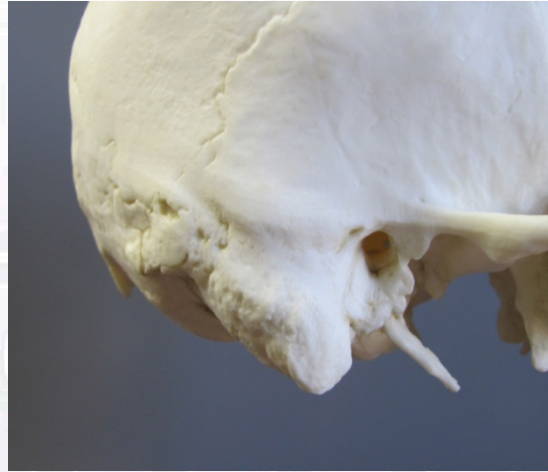

Figure 3: The mastoid process is pronounced, which is often the case in male skulls.

Features of Age:

Since all of the permanent dentition was present, and epiphyseal union was complete, the skeleton was classified as an adult. Criteria such as the morphology of the pubic symphysis, cranial suture closure and analysis of the sternal rib ends were used to estimate age. Pubic symphyseal change is one of the most reliable criteria for estimating age at death in adult skeletal remains. This trait was scored for age using the Suchey-Brooks method (Brooks and Suchey, 1990), with a resulting phase 3 (21 to 46 years) determination. The degree of cranial suture closure was also used, even though there is considerable variability in closure rates (Meindl and Lovejoy, 1989). The partial obliteration of the coronal and sagittal sutures is consistent with a person in his late 20s to early 30s. While difficult to analyze on cast specimens, the costal end of the fourth rib was also observed, and seems to be consistent with Isçan's stage 3-4, which indicates a young adult (mid-20s to early 30s).

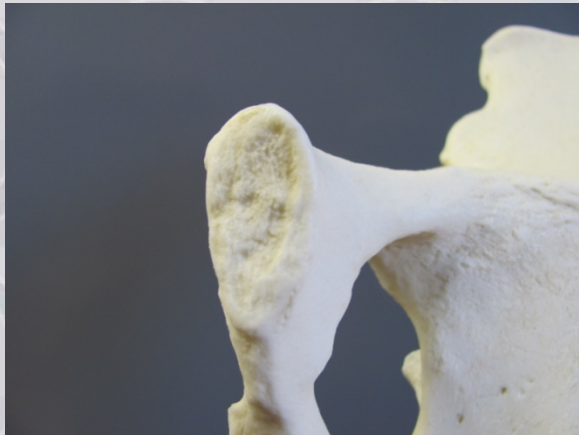

Figure 4: The pubic symphysis.




Figure 5: Superior aspect of the skull showing partial obliteration of the coronal and sagittal sutures.

Features of Ancestry:

Several morphological traits of the skull were used to determine the European ancestry of this individual. For example, the nasion is depressed, the nasal aperture is narrow/vertical, and there is poor dental occlusion (overbite), which are all morphological traits indicative of Europeans. An inion hook is also present, another trait occurring in males of European ancestry.

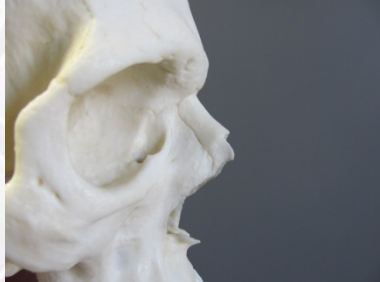

Figure 6: Depressed nasion.

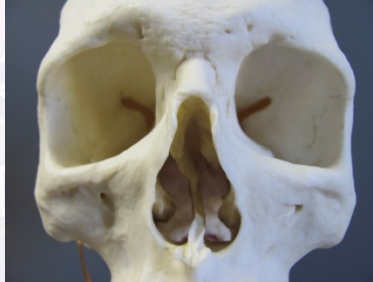

Figure 7: Narrow nasal aperture.



Figure 8: Inion hook.

Stature Estimation:

Since all of the skeletal elements are present, the revised Fully stature estimation technique was used in this case (Raxter et al., 2006), and resulted in a stature estimation of 165.78 cm +/- 4.5 cm ($\approx 5'5'' \pm 1.8''$).

Trauma and Pathology:

There is no evidence of recent trauma. The medial and distal phalanges of the fifth toes (both right and left) are fused, resulting in 25 individual bones in each foot rather than 26.

The deltoid tuberosities are quite pronounced. There is marginal osteophytic lipping on L4 and L5. There are also Schmorl's nodes present on the superior and inferior surfaces of T6 and T8, and the inferior surfaces of T7, T9, T10, and T11.

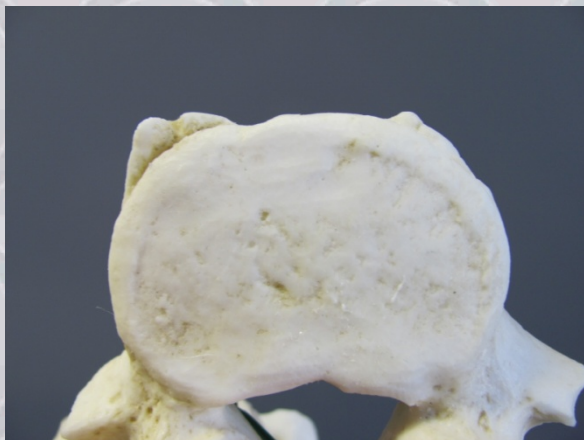

Figure 9: Osteophyte development on the superior margin of L5.



Figure 10: Schmorl's node on the inferior body of T10.

Bone Clones® Osteological Evaluation Report

SUMMARY:

1. Sex: Male
2. Age: Young adult (late 20s to early 30s)
3. Ancestry: European
4. Stature: 161.28 cm - 170.28 cm (≈5'3" to 5'7")
5. Trauma/Pathology: Two fused fifth toes, vertebral osteophyte development, and Schmorl's nodes

Educational Resources:

1. This is an excellent example of an adult male skeleton.
2. All of the developmental skeletal changes are complete, but very few degenerative changes have begun. This makes this skeleton a good candidate for discussing and observing morphological traits in young to middle-aged adults.
3. Since all of the skeletal elements are present, this is a good skeleton to use when discussing the importance of looking at the entire skeleton when assessing sex, age, and ancestry. For example, even though the pelvis is the most reliable indicator of sex, it is still important to look at other aspects of the skeleton. Integrating data from a variety of sources is a good practice, and it will give the most reliable results.

References:

- Bass WM. 1995. *Human osteology: A laboratory and field manual of the human skeleton*. Columbia: Missouri Archaeological Society.
- Brooks ST, Suchey JM. 1990. Skeletal age determination based on the os pubis: A comparison of the Acsádi-Nemeskéri and Suchey-Brooks methods. *Human Evolution* 5:227-238.
- Buikstra JE, Ubelaker DH. 1994. *Standards for data collection from human skeletal remains: Proceedings of a seminar at the Field Museum of Natural History*. Fayetteville: Arkansas Archeological Survey Press.
- İsçan MY, Loth SR, Wright RK. 1984. Age estimation from the ribs by phase analysis: White males. *Journal of Forensic Sciences* 29:1094-1104.
- Mays SA. 1998. *The archaeology of human bones*. London: Routledge.
- Meindl RS, Lovejoy CO. 1989. Age changes in the pelvis: Implications for paleodemography. İsçan MY, editor. *Age markers in the human skeleton*. Springfield, Illinois: Charles C. Thomas. p 137-168.
- Phenice TW. 1969. A newly developed visual method of sexing the os pubis. *American Journal of Physical Anthropology* 30:297-302.

Bone Clones® Osteological Evaluation Report

Raxter MH, Auerbach BM, Ruff CB. 2006. Revision of the Fully technique for estimating statures. *American Journal of Physical Anthropology* 130:374-384.

Schwartz JH. 1995. *Skeleton keys: An introduction to human skeletal morphology, development, and analysis*. New York: Oxford University Press.

White TD, Folkens PA. 2000. *Human osteology*. San Diego: Academic Press, Inc.

Disclaimers:

This report is meant only as a teaching tool for introductory level students of the anatomical, anthropology, or forensic sciences who may be using this specimen to learn about human osteology. Evaluation of skeletal material is best done with original specimens. My evaluation was based solely upon studies of a Bone Clones® replica. My opinions are based solely upon the material presented to me. This is somewhat artificial as in real forensic or archaeological investigations, additional studies would be undertaken prior to the formulation of diagnoses and the production of a report. These studies might include plain film radiography, computed tomography (CT) studies, histology, etc. My opinions regarding sex and ancestry are based only upon non-metric analyses.